

PALEOSCENE 13. Paleopathology of Vertebrates: Insights to Lifestyle and Health in the Geological Record

Bruce M. Rothschild et Darren Tanke

Volume 19, numéro 2, juin 1992

URI : https://id.erudit.org/iderudit/geocan19_2art04

[Aller au sommaire du numéro](#)

Éditeur(s)

The Geological Association of Canada

ISSN

0315-0941 (imprimé)

1911-4850 (numérique)

[Découvrir la revue](#)

Citer cet article

Rothschild, B. M. & Tanke, D. (1992). PALEOSCENE 13. Paleopathology of Vertebrates: Insights to Lifestyle and Health in the Geological Record. *Geoscience Canada*, 19(2), 73–82.

Résumé de l'article

Study of ancient disease (paleopathology) is a powerful tool for understanding lifestyle and population dynamics, as well as the history of disease in antiquity. The major premise of paleopathology is that diagnoses of conditions of living animals can be extrapolated to fossils. Recognition of persistence of structural integrity, and even of cellular components, allows use of new radiologic, immunologic, DNA and holistic analysis techniques to effectively test diagnostic impressions. Collaboration by specialists in structural relationships (e.g., paleontologists) and students of disease (e.g., healthcare providers) provides significant insights to behaviour of animals, long since extinct.



PALEOSCENE 13. Paleopathology of Vertebrates: Insights to Lifestyle and Health in the Geological Record

Bruce M. Rothschild
Arthritis Center of Northeast Ohio
and Northeastern Ohio Universities
College of Medicine
5701 Market Street
Youngstown, Ohio USA 44512

Darren Tanke
Royal Tyrrell Museum of Palaeontology
P.O. Box 7500
Drumheller, Alberta T0J 0Y0

SUMMARY

Study of ancient disease (paleopathology) is a powerful tool for understanding lifestyle and population dynamics, as well as the history of disease in antiquity. The major premise of paleopathology is that diagnoses of conditions of living animals can be extrapolated to fossils. Recognition of persistence of structural integrity, and even of cellular components, allows use of new radiologic, immunologic, DNA and holistic analysis techniques to effectively test diagnostic impressions. Collaboration by specialists in structural relationships (e.g., paleontologists) and students of disease (e.g., health care providers) provides significant insights to behaviour of animals, long since extinct.

INTRODUCTION

Paleopathology examines diseases and other conditions in antiquity (Monastersky, 1990; Moodie, 1923, 1930; Rothschild, 1989a, 1989b; Sawyer and Erickson, 1985). It was a term originally applied to speculation about the cause of alterations in isolated bones. Early diagnostic impressions (e.g., Moodie, 1923) have frequently been found to be erroneous, as modern definitions and technology are applied (Rothschild, 1992). Paleopathology has evolved from such observational speculation to the rigorous testing of scientific hypotheses (Rothschild and Martin, 1992a).

Efforts to assess the impact of pathology have demonstrated the relative rarity of most

forms of pathology. As wellness is the dominant feature of neonatal medicine (since most of the babies are relatively healthy), so too the term paleopathology is perhaps a misnomer. Most animals are healthy. While diseases occasionally afflict significant proportions of the population (e.g., 20% of gorillas have spondyloarthropathy; Rothschild and Woods, 1989), most animal populations are without obvious evidence of disease.

While injuries and fusions predominated in early reports (Brown and Schlaikjer, 1937; Moodie, 1923; Tyson, 1977), the field has greatly expanded. Paleopathology has reached from the ridiculous to the sublime. For example, there was an appropriately anonymous (1934) suggestion that evolution of "freak" features (such as the frills in horned dinosaurs) was related to overproduction of growth hormone (acromegaly). In modern times, the extraordinary possibilities of the field are exemplified by detection of collagen in 200 million-year-old dinosaur bones (Wyckoff, 1980) and DNA in Pleistocene mammals (Paabo, 1989).

In the same way that study of dinosaur footprint patterns has proved enlightening about dinosaur lifestyle (e.g., gait and herd behaviour; Lockley, 1986, 1989), study of paleopathology can provide additional details on dinosaur lifestyle and behaviour. Study of pathology within populations not only allows a more complete perspective of the disease, but also provides insight to the treatment of a

diseased animal by its "peers". Survival of animals with injuries or diseases limiting their mobility and function suggests the possibility of a "support system" which allowed their survival.

A major premise of paleopathology is that human diagnoses can be extrapolated to other genera. This premise is supported by recent demonstration of the psoriatic form of spondyloarthritis in gorillas (Rothschild and Woods, 1989). Identical population frequency, sex ratio, radiologic appearance, pattern of involvement, nature of the lesions, and association with other disease features allowed unequivocal diagnosis. This extrapolation has been validated in contemporary non-human primates, Pleistocene mammals, and Tertiary reptiles (Rothschild, 1987b, 1988, 1990b; Rothschild and Martin, 1987; Rothschild, 1991). Insufficient fish and amphibians have been studied to assess the validity of the hypothesis in those phyla.

Collaborative efforts by functional morphologists (e.g., paleontologists) and students of disease (e.g., health care providers) have provided significant new insights, pursuant to Sigerist's (1951) suggestion of such an approach involving physicians, veterinarians, botanists, geographers, meteorologists, agronomists, entomologists and geologists. Posture, gait, and even habits (Johnson, 1990; Tanke, 1991a, 1991b) are now amenable to study.

The past seven decades have witnessed

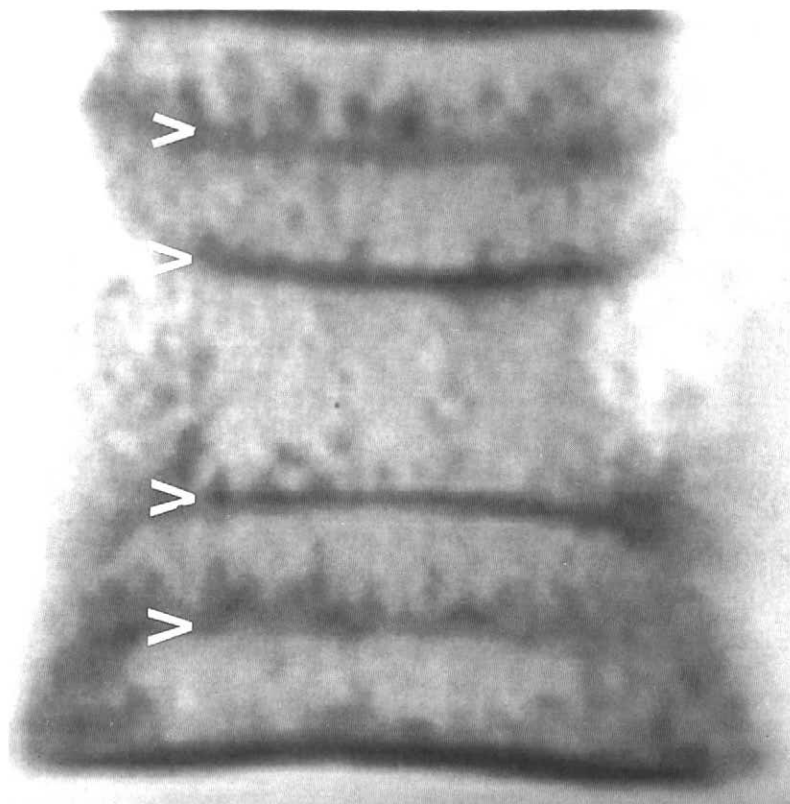


Figure 1 Magnetic resonance image of vertebrae of the Miocene whale, *Eurinodelphis*, illustrating growth recovery lines (arrow heads). (From Sebes et al., 1991).

advances in technology (Rothschild, 1991, 1992a) and the recognition of the importance of global or holistic analysis. Persistence of structural integrity in fish of 300 Ma and in dinosaurs (Dollo, 1887; Romer, 1964; Schultz, 1989), and of subcellular details in Eocene insects (Paabo *et al.*, 1988; Poinar and Hess, 1982) and Pleistocene mammals (Oakley, 1955; Randall *et al.*, 1952; Rowley and Rich, 1986) allows in-depth analysis. Immunologic and DNA techniques now permit even greater opportunities for phylogenetic and disease-related analyses (Higuchi and Wilson, 1984; Paabo *et al.*, 1988; Rothschild and Turnbull, 1987).

While routine radiologic techniques are quite applicable to paleontology (in spite of Moodie's (1923, 1927) initial misgivings), computerized tomographic (CT) scanning techniques "cut" the specimen non-destructively, allowing three-dimensional reconstructions and visualizations of fossils (Conroy and Vannier, 1985; Farrell and Zappulla, 1989). While full preparation of the fossil can commonly be by-passed, it must be noted that the resolution of CT scanning techniques is only 1 mm. Magnetic resonance imaging (MRI) techniques (Fig. 1) can now be applied to fossils (Sebes *et al.*, 1991). Interior structures can be visualized in three dimensions with either technique; that portion of the structure that blocks viewing is digitally removed (Farrell, 1983; Frank *et al.*, 1987; Woolson *et al.*, 1986). The structure can be visualized from almost any perspective (Farrell and Zappulla, 1989) and three-dimensional models can even be generated (Roberts *et al.*, 1984). The non-destructive nature of this approach allows analysis of specimens too valuable to examine directly.

The main purpose of this article is to briefly review paleopathological aspects of some vertebrates and alert the reader to the various methods of examination available for the study of paleopathology. The review will focus on those disorders which are identifiable and have been found in fossil record. For example, although there are perhaps 200 varieties of arthritis which affect humans, most are not known to produce any bony alterations (Resnick and Niwayama, 1988; Rothschild, 1982) and therefore cannot be evaluated in fossils. Paleoparasitology (coprolite analysis) (Brothwell and Sandison, 1967) and possible dinosaur egg pathologies (Hirsch *et al.*, 1989) will not be reviewed.

OSTEOARTHRITIS

Osteoarthritis is the current name applied to the so-called degenerative joint disease of early studies (Moskowitz *et al.*, 1984). The term degenerative seems inappropriate since overgrowth of bone, rather than bone resorption, occurs. Osteoarthritis is recognized by remodelling with spur (osteophyte) formation (Fig. 2), and occasionally by grooving or eburnation of the articular surface. Examination of specimen cross-section

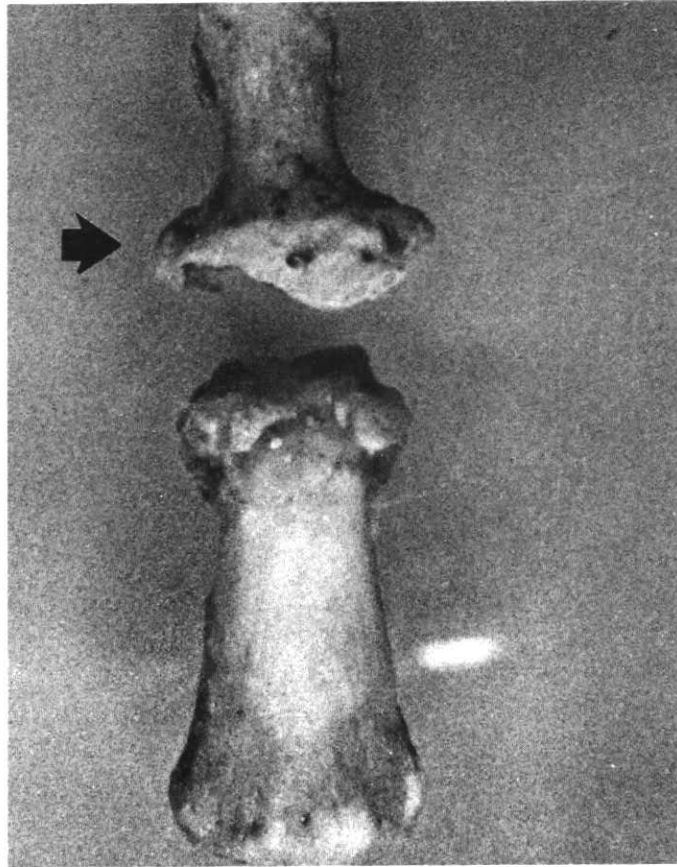


Figure 2 Dorsal view of human distal interphalangeal joint. Remodelling and osteophyte formation (arrow) are noted.

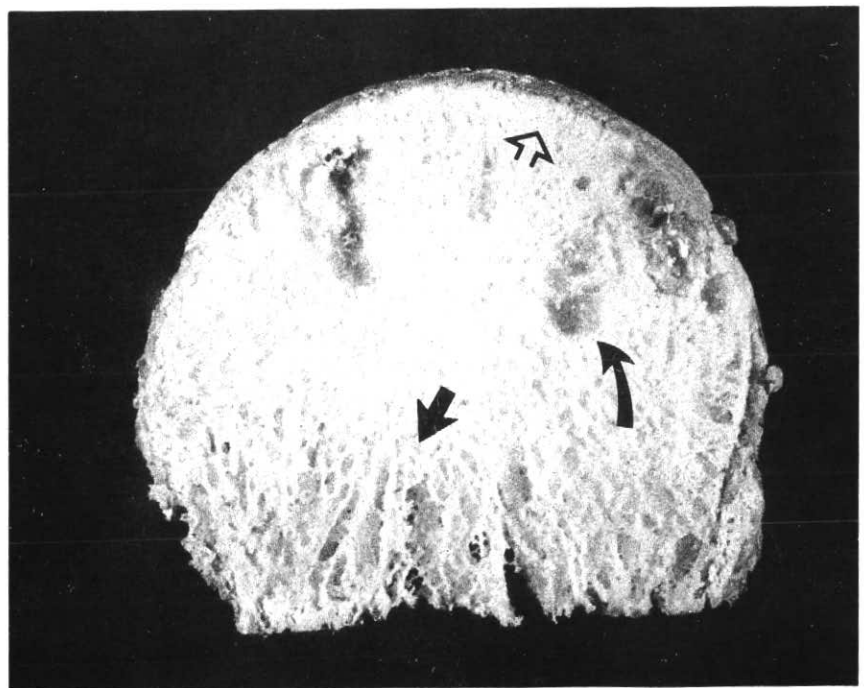


Figure 3 Cross-section of human proximal femur (hip). Increased bony plate density (open arrow) indicates subchondral sclerosis, compared with less dense normal underlying bone (closed arrow). Cyst formation (curved arrow) is also prominent.

tions (e.g., radiologic or actual destructive sectioning of the specimen) reveals increased density in that portion of bone just under the cartilage surface of the joint. Cysts in adjacent bone may also be present (Fig. 3). Spurs (osteophytes) form at articular margins as bony overgrowths. Osteoarthritis is the most common form of arthritis in humans, affecting 20% of the population (Moskowitz *et al.*, 1984; Rothschild, 1982).

Imprecise use of terminology in the medical literature has compromised investigation of osteoarthritis. Although the cartilage damage in osteoarthritis may be called erosive (Moskowitz *et al.*, 1984), this terminology only applies to the cartilage lesions. Actual bone erosions do not occur in osteoarthritis (Resnick and Niwayama, 1988; Rothschild, 1982). Failure of the medical literature to clearly separate use of the term erosive for cartilage, from that for diseases causing bone erosions, has led to a great deal of confusion (Brothwell and Sandison, 1967; Hudson *et al.*, 1975). Unrelated erosive diseases of bone have thus remained unidentified or have been inappropriately included in the catch-all category of osteoarthritis.

Original misidentification of osteoarthritis in dinosaurs as a common phenomenon (Jurmain, 1977) was also related to another pro-

blem of semantics (Rothschild, 1989b, 1990). Spinal osteophytes, common in dinosaurs and marine reptiles (e.g., pliosaurus), indicate *spondylosis deformans*, a very different phenomenon from the disease we today recognize as osteoarthritis. *Spondylosis deformans* (Fig. 4) affects the vertebral disc space, which is not a "joint". Without a joint, arthritis cannot be diagnosed. The asymptomatic nature of spinal osteophytes (Rothschild, 1989b, 1990) further distinguishes them from the joint disease, osteoarthritis.

Osteoarthritis was actually extremely rare in dinosaurs (Rothschild, 1990), although commonly noted in Quaternary mammals (Rothschild, 1992; Rothschild and Martin, 1992a, 1992b; Rothschild and Molnar, 1988). Paradoxically present in pterosaurs (Bennett, 1991), it was totally absent in studied sauropods (Rothschild, 1991). The only documentation in terrestrial dinosaurs has come from two individuals from the 39-member *Iguanodon* herd excavated from a coal mine in Bernissart, Belgium (Fig. 5). Absence of osteoarthritis in weight-bearing bones of dinosaurs has been attributed to the highly irregular bony articular surfaces and the large cartilaginous cap, which would have been necessary to provide a smooth surface for articulation. Weight-bearing joints were

not affected in pterosaur osteoarthritis. Finding osteoarthritis in pterosaurs limited to the wrist area, Bennett (1991) suggested that they were incompletely adapted for flight. Certainly, occurrence of osteoarthritis at the major fulcrum for flight muscle activities suggests significant interference with flight capability.

INFECTIONS

Bone infections are recognized because of the special nature of new (reactive) bone formation. The affected bone is often grossly distorted and may be associated with a filigree type of bone reaction (Fig. 6). Infections are rarely recognized in the fossil record. An infected traumatic amputation of a toe has been suggested for the Upper Jurassic theropod *Allosaurus* (Petersen *et al.*, 1972), and injuries causing digit loss are also known from archeological material (Baker and Brothwell, 1980). Bone infections (probably from compound fractures) have been rarely found in hadrosaurian (duckbill dinosaur) hands (Moodie, 1926). That rarity suggests that infected fractures were either rare events related to predominantly bipedal (Galton, 1970; Norman, 1989), rather than quadrupedal, posture (Coombs, 1978; Paul, 1987), or that they were incompatible with survival.

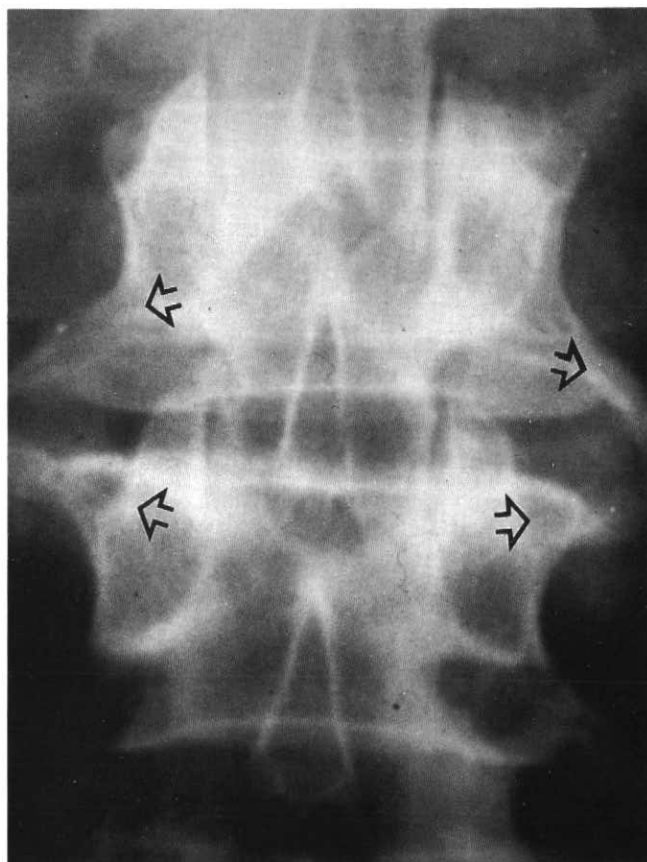


Figure 4 Anterior-posterior x-ray view of human spine. Osteophytic spurs (open arrows) identify presence of *spondylosis deformans*.

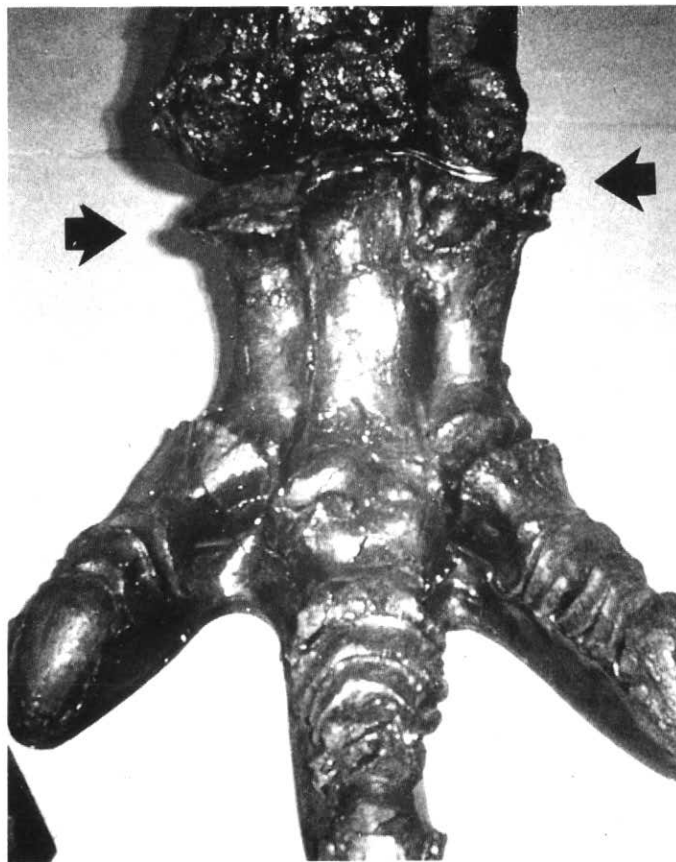


Figure 5 Anterior view of *Iguanodon* foot. Ankle osteophyte formation (osteoarthritis) is noted (arrows). (From Rothschild, 1989a).

DENTAL ABNORMALITIES

Moodie (1930) described dental abscesses in two unassociated hadrosaur jaws now referred to *Lambeosaurus* (Olshevsky, 1978). The abscesses in one formed a deep rounded pocket, producing a prominent bulge on the external surface. Teeth were lost and the toothrow grooves destroyed or misaligned. These examples appear to represent isolated occurrences. Abscesses are extremely rare in the fossil record. Those in the mammalian fossil record are commonly referred to as "lumpy jaw" and appear related to actinomycosis (Moodie, 1922).

Rather than spreading from a cavity, most abscesses probably occurred as the result of injury. Dental cavities were not observed in thousands of hadrosaur tooth specimens in Royal Tyrrell Museum collections. Hadrosaurs constantly replaced their teeth throughout their lifetime, as apparently did all dinosaurs (Edmund, 1960). Worn or spent and expelled hadrosaur teeth are extremely common finds in bonebeds and microfossil assemblages (Dodson, 1983). It is likely that a hadrosaur, with its complex dental battery of hundreds of interlocking teeth, went through many thousands of teeth during its lifetime (Edmund, 1960). Thus, teeth would normally have been worn down and expelled before dental caries could develop (Moodie, 1930).

FUSIONS

The first three cervical vertebrae in large, mature ceratopsians are fused (Fig. 7) into one solid unit (the "cervical bar" of Lehman, 1989). The purpose perhaps was to facilitate carrying the great weight of the head. Incomplete cervical bar fusion has been noted in smaller (presumed younger) *Chasmosaurus*, "*Monoclonius*", *Pachyrhinosaurus* and *Triceratops*. Larger representatives (presumed older individuals) of those genera had completely fused cervical bars (Rothschild, 1987a; Tanke, 1991b). Although cervical fusion appears to be a shared derived feature for *Chasmosaurus*, "*Monoclonius*" and *Triceratops*, that in *Pachyrhinosaurus* also occurs in large (apparently adult) specimens. Fused cervicals have been reported from the type specimen (ANSP 15800) of the diminutive (body length 2.3 m) *Avaceratops lammeri* (Dodson, 1986). If this form is actually an immature specimen of *Centrosaurus* or *Styracosaurus*, as seems possible, then the conclusion that the fusion is an adult feature can be brought into question.

OSSIFIED TENDONS

Ossified tendons have been variously reported as paleopathological or protective (Moodie, 1927, 1928; Rothschild, 1987b). This phenomenon (Fig. 8) is referred to in humans as diffuse idiopathic skeletal hyperostosis (Resnick and Niwayama, 1988; Rothschild, 1982). Present in 15-25% of older mammals, it was ubiquitous in many genera of dinosaurs, including ceratopsians, hadrosaurs,

iguanodonts and pachycephalosaurs (Moodie, 1927; Rothschild, 1985, 1987a, 1987b). While some view the ossified structures in theropods simply as extensions of zygapophyses, haemal or neural arches, these structures appear quite similar in structure and function to the tendon ossification phenomenon in other genera. Tendon ossification apparently occurs early in development, having been documented in juveniles and even in an embryonic duckbilled dinosaur (?*Hypacrosaurus*) (P.J. Currie, pers. comm., 1990). These ossification phenomena are not pathologic, and may even be protective (Rothschild, 1985).

Apparently analogous to such tendon ossification is the phenomenon noted in per-

haps 50% of sauropods (Rothschild and Ber- man, 1991), whereby two to four contiguous caudal vertebrae are fused by new bone. Localization of fusion to a segment of tail between the 15th and 25th caudal vertebrae (Fig. 9), and not affecting the zygapophyseal (facet) and costo-vertebral joints, supported this perspective. Radiological visualization of a clear space between the ossification and the vertebral body confirmed the diagnosis as diffuse idiopathic skeletal hyperostosis (DISH). Computerized scanning of multiple specimens (Fig. 10) and physical cutting of a longitudinal section of American Museum of Natural History specimen #655 (*Diplodocus*) revealed the anticipated separation of the ossifi-




Figure 6 Lateral view of *Anchiceratops* orbital horn core. Filigree reaction (arrowhead) and periostitis are noted.

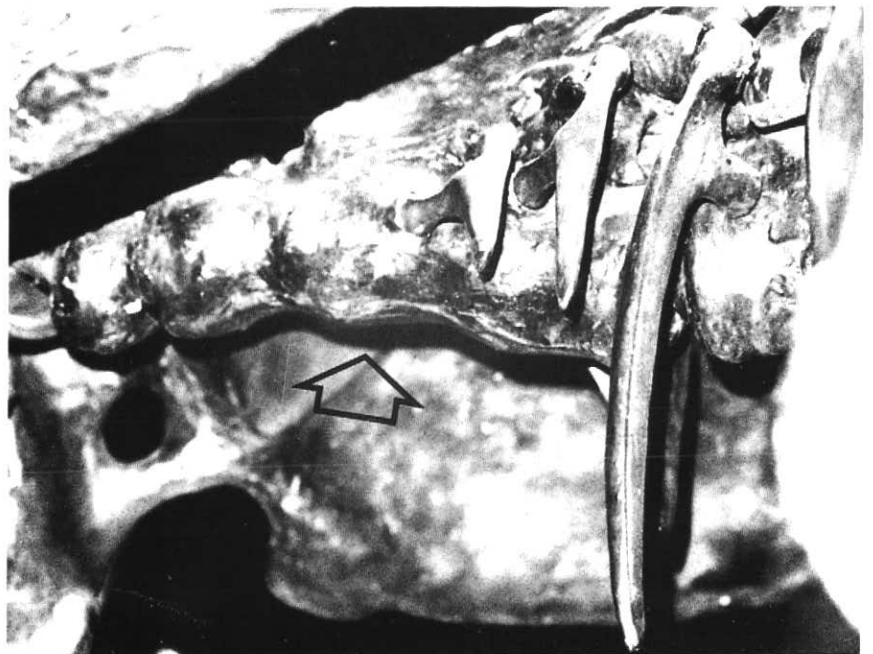


Figure 7 Inferior-lateral view of *Triceratops* cervical spine. Fusion of first three cervical vertebrae (open arrow) is noted.

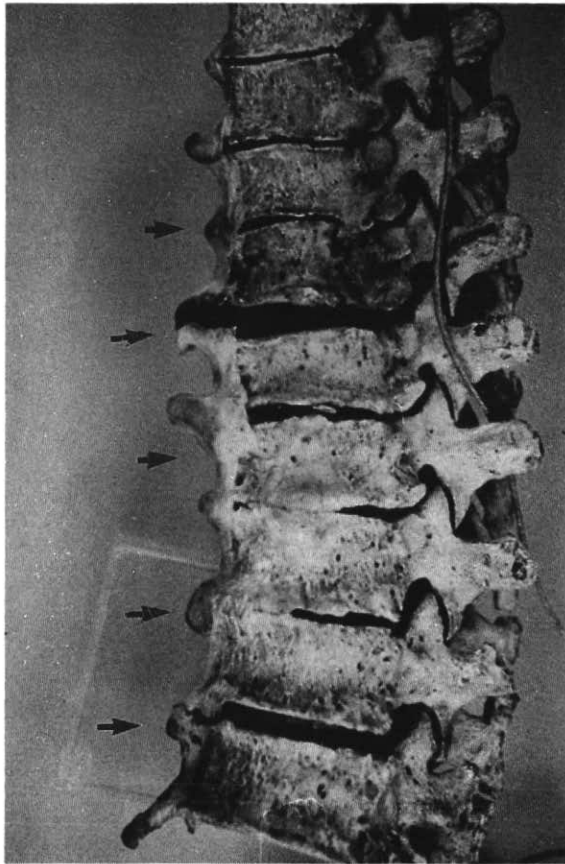


Figure 8 Lateral view of human thoracic spine. Candle wax-like paraspinal ossification (arrows) identifies presence of diffuse idiopathic skeletal hyperostosis (DISH).

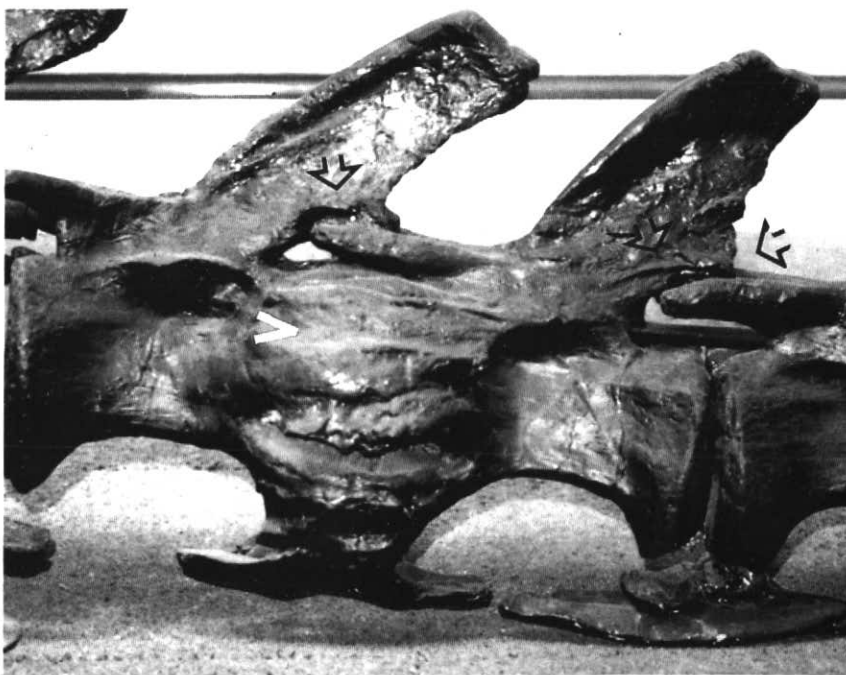


Figure 9 Lateral view of *Diplodocus* caudal vertebrae. Apparent fusion of vertebral bodies (arrowhead) with preservation of normal zygoapophyseal joints (open arrows).

cation from the vertebral body by a thin gap. Presence of DISH at mechanically stressed points confirms the interpretation of trackway records: sauropods did not drag their tails on the ground, but kept their tails in the air (Bakker, 1968; Thulborn and Wade, 1984). The position of fusion (two-fifths of the distance from the sacrum to the most distant caudal vertebrae) represents the optimal position for "buttressing" a cantilever structure. The outstretched tail of the dinosaur presents that appearance. While tail fusion may have had a defensive function (Hatcher, 1901; Holland, 1915), it is perhaps more likely that the fusion was important in intra-species territorial or courting competition or even for mating (Rothschild, 1987a, 1987b; Rothschild and Berman, 1991).

TUMORS

Abnormal bony surface projections are referred to as exostoses. One form of exostosis, alternatively considered a form of tumor, is the osteochondroma. It is recognized by the mushroom appearance of the subchondral exostotic bone. When more than one bone is affected, it is called multiple hereditary osteochondromata. This autosomal dominant human disorder has also been found in 46% (13 of 27) of Oligocene *Hesperocyon gregarius* (Wang and Rothschild, 1990). While such osteochondromata have been previously diagnosed in the monitor lizard, horse, domestic dog and possibly the Oligocene canid *Daphoneus* (Romer, 1924), their confirmed distribution has now been expanded to Oligocene canids.

Benign bone tumors called button osteomas resemble knobs of adherent bone. They are extremely rare. We have seen one in a mosasaur. We are unaware of any valid report of a malignant bone tumor in the fossil record, although one may exist.

AVASCULAR NECROSIS AND DECOMPRESSION SYNDROME

Loss of blood supply to bone results in liquefaction and a relatively uniform loss of bony matrix in the downstream region of the vascular system (Feldman *et al.*, 1981; Resnick and Niwayama, 1988; Rothschild, 1982). This produces zonal losses of bone density, easily recognized on sectioning or x-ray (Fig. 11). When the proximal femur or humerus is affected, mechanical integrity is compromised and the overlying subchondral bone collapses. Recently described in Cretaceous mosasaurs (Rothschild and Martin, 1987), the phenomenon has also been identified in marine turtles (Rothschild and Martin, 1992a). Avascular necrosis of bone has been documented in eight families of marine/aquatic turtles from the Cretaceous (Rothschild and Martin, 1992a) to Recent. The Cretaceous families Desmatochelyidae, Toxochelyidae, Protostegidae and Pleurosternidae were especially affected. Subsequent reduction in frequency of avascular necrosis in the Early Eocene was followed by

near disappearance, subsequent to the Oligocene (Rothschild and Martin, 1992a). Its occurrence in contemporary turtle families such as Cheloniidae (*Lepidochelys*), Chelydridae (*Chelydra* and *Macrochelys*) and Kinosternidae (*Kinosternon*) is at even lower frequencies than that of the Oligocene.

Septic necrosis in the turtle *Dermochelys* (Ogden *et al.*, 1981) may reflect a similar susceptibility to avascular necrosis, but inadequate numbers of individuals have been available to assess that question to date. *Dermochelys*, which dives almost continuously to depths of 474 m, with surface intervals of only three seconds (Lenfant *et al.*, 1970), is likely to be susceptible to avascular necrosis.

Absence of avascular necrosis (Rothschild and Martin, 1992a) in non-diving turtles (*e.g.*, Trionychoidea) supports the diving hypothesis as etiologic for the noted avascular necrosis. Limitation of this phenomenon to turtles, mosasaurs and humans and its absence in other reptiles and in mammals are striking. If Scholander's hypothesis is correct that diving mammals are inherently susceptible to decompression syndrome (see Kooyman and Sinnett, 1982), the extant and fossil records perhaps provide an opportunity to identify protective adaptations.

Such adaptations, described by Chrysanthou *et al.* (1974), Rothschild (1987a), Strauss (1970), Strauss and Sampson (1986), and White (1970), include: inhalation prior to diving; modifications affecting lung collapse, vascular supply, viscosity, or permeability; cutaneous respiration/gas exchange; and metabolic changes. The latter include coag-

ulation factors, heparin, and susceptibility of complement activation responses to microbubble formation. While these adaptations cannot be directly measured in the fossil record, the fossil record does provide a novel approach. Adaptation can be studied in extant descendants of individuals identified as afflicted in the fossil record.

FRACTURES

Fractures have long figured in paleopathology (Brown and Schlaikjer, 1937; Moodie, 1923; Tyson, 1977), and the field has greatly expanded. They are, however, relatively rare (Blows, 1989; Tanke, 1991b; Vance, 1989).

Stress fractures are caused by periods of "unconditioned" strenuous activities or repetitive activities (Resnick and Niwayama, 1988; Rothschild, 1982). The appearance of periosteal reaction with oblique radiolucent clefts (detected by x-ray or cross-sectioning) is diagnostic. Observation of a stress fracture in an isolated phalanx from a ceratopsian from Dinosaur Provincial Park (Rothschild, 1988) stimulated evaluation of bone beds to determine the frequency of the phenomenon in the population. Stress fractures, localized to the proximal phalanges of digits II-IV, have now been recognized in species of *Centrosaurus*, *Styracosaurus*, *Pachyrhinosaurus* and *Triceratops*. Localized to the main weight-bearing bones of the foot, these fractures may have occurred subsequent to foot stamping or to episodes of sudden acceleration (*e.g.*, to escape predators). This localization is similar to so-called march fractures in humans. Stress fractures have been limited to humans, race horses and racing

greyhounds. Their only documentation in the fossil record is in ceratopsians.

INJURIES THROUGH INTRA- AND INTERSPECIES INTERACTIONS

Perspectives on aggressive behaviour in centrosaurines and chasmosaurines (horned dinosaurs) have been questioned on the basis of paleopathologic evidence. Some investigators suggested that injuries were a regular occurrence (Alexander, 1989; Currie and Dodson, 1984; Ostrom, 1986; Russell, 1935). Farlow and Dodson (1975) alternatively suggested that centrosaurines (analogous to extant horned ungulates) were possibly more solitary in habit and indicated that relative difficulty in blocking nasal horn strikes from an adversary might result in more frequent injuries in centrosaurines. Recent studies show that greater frequency of injuries has not been found in centrosaurines, compared to chasmosaurines (Tanke, 1991b). Actually, pathology (other than stress fractures) was extremely rare among 30,000 elements examined from *Centrosaurus*, *Styracosaurus* and *Pachyrhinosaurus* (0.025-0.5% of *Centrosaurus*, 0.2-1.0% of *Pachyrhinosaurus*) (Tanke, 1991b).

The predominance of rib and vertebral lesions in hadrosaurs also provides unique behavioural insights (Tanke, 1991a). The most common injuries seen in the hadrosaur fossil record are damaged and rehealed or rehealed proximal caudal neural spines, and caudal fusions. Norman (1980) has noted "not uncommon" occurrences of pathological fusions involving two caudal centra in the large Lower Cretaceous ornithomimid *Iguano-*

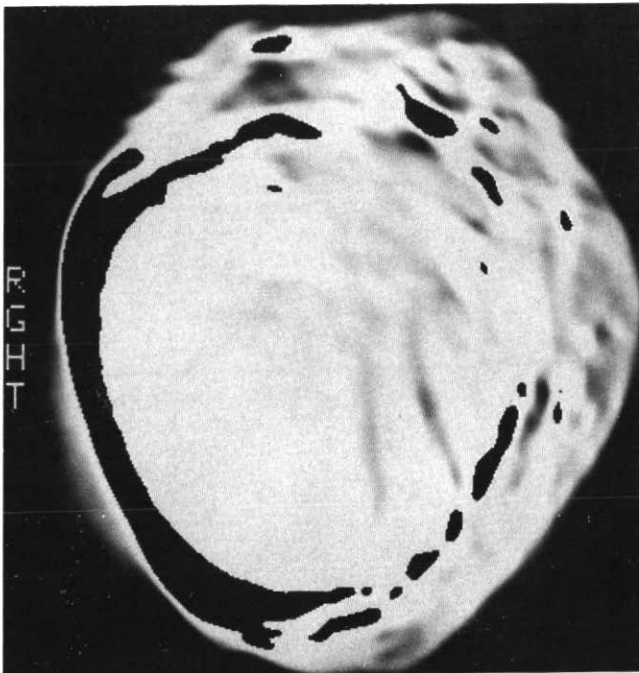


Figure 10 CT image of *Diplodocus* caudal vertebrae. The ossification, though circumferential, is demonstrated to be physically separate from the vertebral body. Black spaces identify the separation.

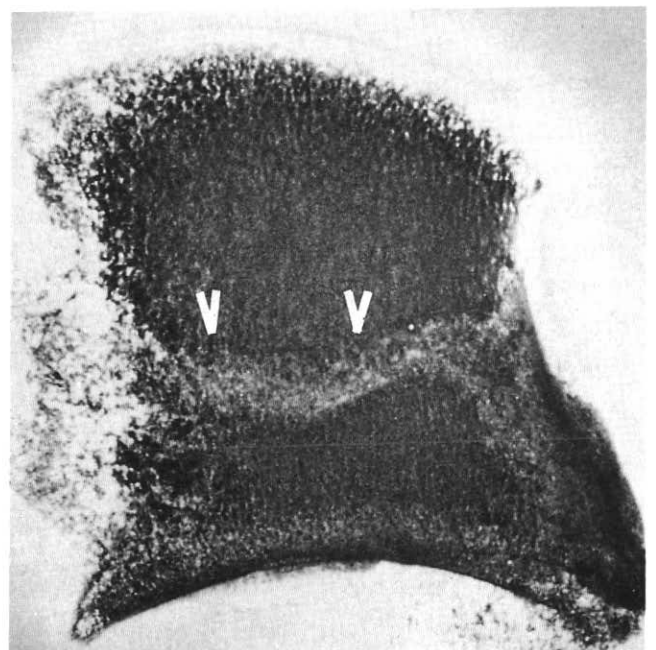


Figure 11 Lateral x-ray of mosasaur vertebrae. Band of decreased density (arrowhead) bisecting specimen identifies avascular necrosis.

don. Teeth marks are rarely identified; most changes do not appear attributable to predation. Intraspecific activities are most likely responsible.

Attempts to correlate paleopathologies with behaviour — especially intraspecific fighting — have included descriptions of cranial injuries in the Pleistocene Dire Wolf

(Moodie, 1923; Courville, 1953), the musk ox (Nelson and Madsen, 1978), the proboscideans *Mammuthus* and *Mastodon* (Macdonald, 1951; Moodie, 1923), Oligocene rhinocerotid *Amphicaenopus* (Bjork, 1978), Oligocene entelodonts (Green, 1961), Eocene crocodiles (Buffetaut, 1983), the Lower Jurassic eosuchian *Gephyrosaurus*

(Evans, 1983), and the Triassic phytosaur *Mystriosuchus plieningeri* (Moodie, 1923). While some early attempts at behavioural analysis were perhaps fanciful, many appear quite reasonable. Unfortunately, studies to determine the population frequency of these phenomena have been predominantly limited to dinosaurs.

Courtship behaviour between sexes of taxonomically diverse extant vertebrates involves complex displays and (in some cases) violent fighting prior to mating (Droscher, 1976). In extant ungulates, most true fighting (not rutting or sparring behaviour) between males that results in injuries or death occurs during harem acquisition or protection (Geist, 1974). Serious fighting is a fact of life for many extant vertebrates, and such may have also been the case with hadrosaurs and other dinosaurs. Non-lethal fighting in hadrosaurs may have played a role in population regulation, as is the case in a variety of extant vertebrates and invertebrates (Harris, 1989). The most common bone paleopathology in centrosaurines was mid- and posterior dorsal rib fractures. Similarly, broken ribs are not infrequent in adult male American buffalo (McHugh, 1958), a species known to engage in side-butting behaviour (Fuller, 1960). Flank butting (Fig. 12) is similarly suggested by the fracture pattern in centrosaurines and possibly chasmosaurines (Tanke, 1991b).

Injuries caused during mating have been suggested for dinosaurs. Gilmore (1909, 1912) cited bone injuries to the right ilium and basal tail of the Late Jurassic ornithomimid *Camptosaurus browni* (USNM 4282) as possibly being borne by, "... a female who might have received the injuries during copulation". Blows (1989) has suggested an ischial fracture in the large ornithomimid *Iguanodon* may have occurred during mating. Vance (1989) considered the not infrequent breakage of humeri of predatory tyrannosaurid dinosaurs as the result of accidents during mating. Alternatively, Molnar and Farlow (1990) thought such lesions were related to struggles with prey. Droscher (1976) has cited numerous examples of aggressive behaviour in extant animals during courtship and mating. Baker and Brothwell (1980) include trauma during mating as one of numerous factors responsible for bone pathologies in recent vertebrates.

Mating activities may be responsible for the proximal caudal neural spine pathology in hadrosaurs. While some (Halstead, 1975; Alexander, 1989) have speculated on the subject, the postures assumed by mating dinosaurs are not known. It is also uncertain if the males had an extendable hemipenis (as in modern reptiles). An incompletely prepared partial sub-adult hadrosaur skeleton (RTMP 7718.2) from the Campanian Judith River Formation of Lost River, Alberta (with excellent skin impressions near the cloacal region) may solve this mystery for at least that species, once preparation is completed.




Figure 12 Hypothesized side butting behavior in *Pachyrhinosaurus*. Illustration by Tracy Ford, Poway, California.




Figure 13 Speculative drawing illustrating copulating positions of mating pair of sauropods. Illustration by Ron Embleton, courtesy of OMNI Magazine.

However, highly variable body plans of dinosaurs indicate a variety of mating positions (Fritz, 1988). In those forms unhindered by plates, spines and other armour, mating may have been accomplished by the female presenting herself to the male while standing on all fours with the tail raised and turned slightly to one side. According to this view, the male mounted from behind and to the side, one leg swung over the female's hip/proximal tail region. His tail would have curled underneath that of the female, thereby allowing the cloacas to meet, as in the mating posture of *Camptosaurus* (Halstead, 1975). This type of mating posture, or similar variations, is utilized by many extant reptiles (Carpenter and Ferguson, 1977) and, to a lesser degree, by birds. The distribution (Rothschild and Berman, 1991) of caudal fusion (Fig. 9) appears to be evidence for this behaviour in sauropods (Fig. 13). Occurrence of caudal fusion in 50% of *Diplodocus* and *Apatosaurus* suggests the trait represents a sexual dimorphism. Fusion of caudal vertebrae in females would certainly facilitate positioning of the tail so as not to interfere with mating.

If female hadrosaurs presented for mating, standing on all fours with the tail raised and turned slightly to one side, some of the male's weight would have rested directly upon the female's tail base and, in particular, the tips of the neural spines. During body positioning and actual mating, it is possible that some injuries to the female's basal tail spine may have resulted. Lambeosaurines, with their tall caudal neural spines and elongate chevrons, may have been more susceptible to these types of injuries than their hadrosaurine cousins, which had relatively shorter spines and chevrons. Mating and courtship-related injury appears to be the most reasonable hypothesis at this time.

CONCLUSIONS AND IMPLICATIONS

As North American paleontology was transformed from a curiosity to a subject of scientific study by Thomas Jefferson (Rothschild, 1989a), recognition of internal structure and actual biologic preservation in ancient skeletons have transformed paleopathology. The major premise of paleopathology, that diagnostic approaches for extant animal diagnoses can be extrapolated to fossils, has been verified (Rothschild, 1987b, 1988, 1990b, Rothschild and Martin, 1987, 1992a; Rothschild and Berman, 1991). Collaborative efforts by paleontologists, physicians, veterinarians, botanists, geographers, meteorologists, agronomists, entomologists, geologists, immunologists and molecular biologists and technical advances have contributed greatly to this transformation. Extraction and replication of DNA from a mammoth of 40,000 years before present (Paabo, 1989; Thomas *et al.*, 1989) hint at the potential application of molecular biology to study of fossils. Application of medical techniques

has also allowed development of new, non-destructive approaches to anatomical study, at times even eliminating the need to remove the specimen from surrounding matrix.

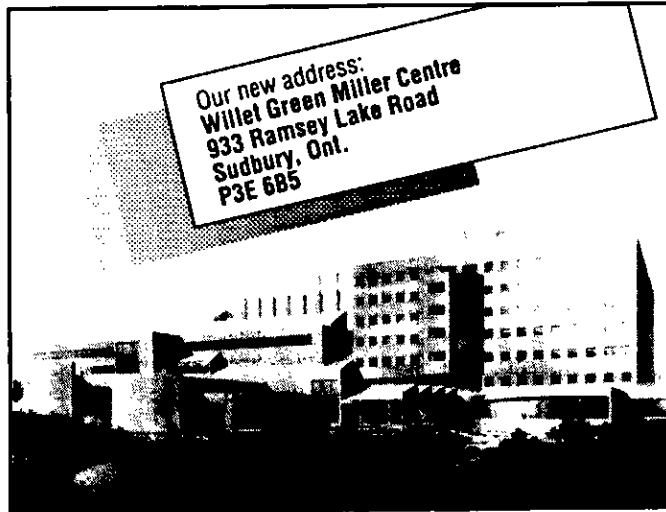
The fossil record not only characterizes species, but provides clues to their behaviour and evolution. Study of this record may also yield information about disease development. Study of osteoarthritis, fusion phenomenon, avascular necrosis, and fractures provide such insights, as well as a perspective on the origins of disease. Following the trail of disease phenomenon through time may reveal clues to contemporary disease and to the genetic and physiological adaptations that control disease susceptibility. New approaches to disease prevention or treatment may evolve.

REFERENCES

- Alexander, R.McN., 1989, Dynamics of dinosaurs and other extinct giants: Columbia University Press, New York, 167 p.
- Anonymous, 1934, Glands may have caused evolution of freak dinosaurs: Science News Letter, v. 25, p. 182.
- Baker, J. and Brothwell, D., 1980, Animal Diseases in Archaeology: Academic Press, London, 235 p.
- Bakker, R.T., 1968, The superiority of dinosaurs: Discovery, v. 3, p. 11-22.
- Bennett, S.C., 1991, Pathologies of the large pterodactylid pterosaurs, in Rothschild, B.M. and Shelton, S., eds., Paleopathology: University of Texas Museum of Natural History, Austin, in press.
- Bjork, P.R., 1978, The functional significance of a broken lower incisor in *Amphicæonopus*, an Oligocene Rhinocerotid: South Dakota Academy of Sciences, Proceedings, v. 57, p. 163-167.
- Blows, W.T., 1989, A pelvic fracture in *Iguanodon*: Archosaurian Articulations, v. 1, p. 49-50.
- Brothwell, D.R. and Sandison, A.T., 1967, Diseases in Antiquity. A survey of the Diseases, Injuries and Surgery of Early Population: Charles C. Thomas, Springfield, Illinois, 766 p.
- Brown, B. and Schlaikjer, E.M., 1937, The skeleton of *Styracosaurus* with the description of a new species: American Museum Novitates, v. 955, p. 1-12.
- Buffetaut, E., 1983, Wounds on the jaw of an Eocene mesosuchian crocodylian as possible evidence for the antiquity of crocodylian intraspecific fighting behavior: Palaontologische Zeitschrift, v. 57, p. 143-145.
- Carpenter, C.C. and Ferguson G.W., 1977, Variation and evolution of stereotyped behavior in reptiles, Part I. A survey of stereotyped reptilian behavioral patterns, in Gans, C., ed., Biology of the Reptilia: Academic Press, London, v. 7, p. 335-403.
- Chryssanthou, C., Teichner, D. and Koutsoyiannis, M., 1974, Studies on dysbarism: V. Prevention of decompression sickness in mice by dimethothiazine: Aerospace Medicine, v. 45, p. 279-282.
- Conroy, G.C. and Vannier, M.W., 1985, Endocranial volume determination of matrix-filled fossil skulls using high-resolution computed tomography, in Lawrence, K.D., ed., Hominid Evolution: Past, Present and Future: Alan R. Liss, Lawrence, Kansas, p. 419-426.
- Coombs, W.P., 1978, Theoretical aspects of cursorial adaptations in dinosaurs: Quarterly Review of Biology, v. 53, p. 393-418.
- Courville, C.B., 1953, Cranial injuries in prehistoric animals — with special notes on a healed wound of the skull in the Dire Wolf (*Canis [Aenocyon] dirus* [Leidy]) and a mortal wound in the California Black Bear (*Ursus americanus*): Los Angeles Neurologic Society, Bulletin, v. 18, p. 117-126.
- Currie, P.J. and Dodson, P., 1984, Mass death of a herd of ceratopsian dinosaurs, in Reif, W.-E. and Westphal, F., eds., Third Symposium on Mesozoic Terrestrial Ecosystems: Verlag, Tubingen, p. 61-66.
- Dodson, P., 1983, A faunal review of the Judith River (Oldman) Formation, Dinosaur Provincial Park, Alberta: The Mosasaur, v. 1, p. 89-118.
- Dodson, P., 1986, *Avaceratops lammersi*: a new ceratopsid from the Judith River Formation of Montana: Academy of Natural Sciences, Proceedings, Philadelphia, v. 138, p. 305-317.
- Dodson, P. and Currie, P.J., 1990, Neoceratopsia, in Weishampel, D., Dodson, P. and Osmlska, H., eds., The Dinosauria: University of California Press, Berkeley, p. 593-618.
- Dollo, L., 1887, Note sur les ligaments ossifies des dinosaures de Bernissart: Archive de Biologie, v. 7, p. 249-264.
- Droscher, V.B., 1976, They Love and Kill — Sex, Sympathy and Aggression in Courtship and Mating: EP Dutton, New York, 363 p.
- Edmund, G., 1960, Tooth replacement phenomena in the lower vertebrates: Royal Ontario Museum, Life Science Contributions, v. 52, p. 1-190.
- Evans, S.E., 1983, Mandibular fracture and inferred behavior in a fossil reptile: Copeia, v. 3, p. 845-847.
- Farlow, J.O. and Dodson, P., 1975, The behavioral significance of frill and horn morphology in ceratopsian dinosaurs: Evolution, v. 29, p. 353-361.
- Farrell, E.J., 1983, Color display and interactive interpretation of three-dimensional data: IBM Journal of Research and Development, v. 27, p. 356-366.
- Farrell, E.J. and Zappulla, R.A., 1989, Three-dimensional data visualization and biomedical applications: CRC Critical Reviews in Biomedical Engineering, v. 16, p. 323-363.
- Feldman, J.L., Menkes, C.J., Amor, B., Cherot, A. and Delbarr, F.L., 1981, Osteonecrosis vertebrale de l'adults: Revue du rhumatisme, v. 48, p. 773-780.
- Frank, J., McEwen, B.F., Radermacher, M., Turner, J.N. and Rieder, C.L., 1987, Three-dimensional tomographic reconstruction in high-voltage electron microscopy: Journal of Electron Microscopic Technique, v. 6, p. 193-205.
- Fritz, S., 1988, *Tyrannosaurus* sex: a love tail: Omni, v. 10, p. 64-68.
- Fuller, W.A., 1960, Behavior and social organization of the wild bison of Wood Buffalo National Park, Canada: Arctic, v. 13, p. 3-19.
- Galton, P.M., 1970, The posture of hadrosaurian dinosaurs: Journal of Paleontology, v. 44, p. 464-476.
- Geist, V., 1974, On fighting strategies in animal combat: Nature, v. 250, p. 354.
- Gilmore, C.W., 1909, Osteology of the Jurassic reptile *Camptosaurus*, with a revision of the species of the genus, and descriptions of two new species: United States National Museum, Proceedings, v. 36, p. 197-332.

- Gilmore, C.W., 1912, The mounted skeletons of *Campiosaurus* in the United States National Museum: United States National Museum, Proceedings, v. 41, p. 687-696.
- Green, M., 1961, Pathologic vertebrate fossils and recent specimens: South Dakota Academy of Sciences, Proceedings, v. 40, p. 142-148.
- Halstead, L.B., 1975, The Evolution and Ecology of the Dinosaurs: Peter Lowe, London, 116 pp.
- Harris, R.N., 1989, Nonlethal injury to organisms as a mechanism of population regulation: *American Naturalist*, v. 134, p. 835-847.
- Hatcher, J.B., 1901, *Diplodocus* (Marsh), its osteology, taxonomy and probable habits, with a restoration of the skeleton: Carnegie Museum, Memoirs, v. 1, p. 1-63.
- Higuchi, R. and Wilson, A.C., 1984, Recovery of DNA from extinct species: *Federation Proceedings*, v. 43, p. 1557.
- Hirsch, K.F., Stadtman, K.L., Miller, W.E. and Madsen, J.H., Jr., 1989, Upper Jurassic dinosaur egg from Utah: *Science*, v. 243, p. 1711-1713.
- Holland, W.J., 1915, Heads and tails: A few notes relating to the structure of the sauropod dinosaurs: Carnegie Museum, Annals, v. 9, p. 273-278.
- Hudson, C., Butler, R. and Sikes, D., 1975, Arthritis in the prehistoric southeastern United States: biological and cultural variables: *American Journal of Physical Anthropology*, v. 43, p. 57-62.
- Johnson, R.E., 1990, Biomechanical analysis of forelimb posture and gait in *Torosaurus*: *Journal of Vertebrate Paleontology*, v. 10, p. 29A-30A.
- Jurmain, R., 1977, Stress and the etiology of osteoarthritis: *American Journal of Physical Anthropology*, v. 80, p. 229-237.
- Kooyman, G.L. and Sinnett, E.E., 1982, Pulmonary shunts in harbor seals and sea lions during simulated dives to depths: *Physiological Zoology*, v. 55, p. 105-111.
- Lehman, T.M., 1989, *Chasmosaurus mariscalensis*, sp. nov., a new ceratopsian dinosaur from Texas: *Journal of Vertebrate Paleontology*, v. 9, p. 137-162.
- Lenfant, C., Johansen, K. and Petersen, J.A., 1970, Respiration in the fresh water turtle, *Chelys fimbriata*: *Respiratory Physiology*, v. 8, p. 261-275.
- Lockley, M.J., 1986, A guide to dinosaur tracksites of the Colorado Plateau and American southwest: University of Colorado, Denver, Geology Department Magazine, Special Issue, v. 1, 56 p.
- Lockley, M.J., 1989, Tracks and traces: new perspectives on dinosaurian behavior, ecology, and biogeography, in *The Age of Dinosaurs: Short Courses in Paleontology No. 2: Paleontological Society*, p. 134-145.
- Macdonald, J.R., 1951, Pathological vertebrates from South Dakota: *Geological Society of America, Bulletin*, v. 62, p. 1539.
- McHugh, T., 1958, Social behavior of the American bison (*Bison bison bison*): *Zoologica*, v. 43, p. 1-40.
- Molnar, R.E. and Farlow, J.O., 1990, Carnosaur paleobiology in Weishampel, D.B., Dodson, P. and Osmolska, H., eds, *The Dinosauria*: University of California Press, Berkeley, p. 210-224.
- Monastersky, R., 1990, Reopening old wounds — physicians and paleontologists learn new lessons from ancient ailments: *Science News*, v. 137, p. 40-42.
- Moodie, R.L., 1922, Actinomycosis in a fossil rhinoceros: *Journal of Parasitology*, v. 9, p. 28.
- Moodie, R.L., 1923, Paleopathology — An Introduction to the Study of Ancient Evidences of Disease: University of Illinois Press, Urbana, 557 p.
- Moodie, R.L., 1926, Excess callus following fracture of the fore foot in a Cretaceous dinosaur: *Annals of Medical History*, v. 8, p. 73-77.
- Moodie, R.L., 1927, Studies in Paleopathology: XX. Vertebral lesions in the sabre-tooth, Pleistocene of California, resembling the so-called Myositis Ossificans Progressiva, compared with certain ossifications in the dinosaurs: *Annals of Medical History*, v. 9, p. 91-102.
- Moodie, R.L., 1928, The histological nature of ossified tendons: *American Museum Novitates*, v. 311, p. 1-15.
- Moodie, R.L., 1930, Dental abscesses in a dinosaur millions of years old, and the oldest yet known: *Pacific Dental Gazette*, v. 38, p. 435-440.
- Moskowitz, R.W., Howell, D.S., Goldberg, V.M. and Mankin, H.J., 1984, Osteoarthritis: Diagnosis and Management: Saunders, Philadelphia, 584 p.
- Nelson, M.E. and Madsen, J.H., Jr., 1978, Late Pleistocene musk oxen from Utah: *Kansas Academy of Sciences, Transactions*, v. 81, p. 277-295.
- Norman, D.B., 1980, On the ornithischian dinosaur *Iguanodon bernissartensis* from the Lower Cretaceous of Bernissart (Belgium): *Institut Royal des Sciences Naturelle de Belgique, Memoirs*, v. 178, p. 1-103.
- Norman, D.B., 1989, Ornithopod dinosaurs: relationships, structure, and habits, in *The Age of Dinosaurs: Paleontological Society, Short Courses in Paleontology*, v. 2, p. 58-72.
- Oakley, K.P., 1955, The associated implements and mammalian remains and the composition of the hominoid remains: *British Museum of Natural History, Bulletin in Geology*, v. 2, p. 254-265.
- Ogden, J.A., Rhodin, A.G., Conlogue, G.J. and Light, T., 1981, Pathobiology of septic arthritis and contiguous osteomyelitis in a leatherback turtle (*Dermodochelys coriacea*): *Journal of Wildlife Disease*, v. 17, p. 277-287.
- Olshevsky, G.O., 1978, The archosaurian taxa: Mesozoic Meanderings, v. 1, p. 1-50.
- Ostrom, J.H., 1986, Social and unsocial behavior in dinosaurs, in Nitecki, M.H. and Kitchell, J.A., eds., *Evolution of Animal Behavior — Paleontological and Field Approaches*: Oxford University Press, New York, p. 41-61.
- Paabo, S., 1989, Ancient DNA: extraction, characterization, molecular cloning, and enzymatic amplification: *National Academy of Sciences, Proceedings*, v. 86, p. 1939-1943.
- Paabo, S., Gifford, J.A. and Wilson, A.C., 1988, Mitochondrial DNA sequences from a 7000-year-old brain: *Nucleic Acids Research*, v. 16, p. 9775-9787.
- Paul, G.S., 1987, The science and art of restoring the life appearance of dinosaurs and their relatives: a rigorous how-to guide, in Czerkas, S.J. and Olsen, E.C., *Dinosaurs Past and Present, Vol. 2: Natural History Museum of Los Angeles County and University of Washington Press*, p. 4-49.
- Petersen, K., Isakson, J.I. and Madsen, J.H., Jr., 1972, Preliminary study of paleopathologies in the Cleveland-Lloyd Dinosaur Collection: *Utah Academy of Sciences, Proceedings*, v. 49, p. 44-47.
- Poinar, G.O. and Hess, R., 1982, Ultrastructure of 40-million-year-old insect tissue: *Science*, v. 215, p. 1241-1242.
- Randall, J.T., Fraser, R.D., Jackson, S., Martin, A.W. and North, A.C., 1952, Aspects of collagen structure: *Nature*, v. 169, p. 1029-1033.
- Resnick, D. and Niwayama, G., 1988, *Diagnosis of Bone and Joint Disorders, Second Edition*: Saunders, Philadelphia, 6444 p.
- Roberts, D., Pettigew, J., Udupa, J.K. and Ram, C., 1984, Three-dimensional imaging and display of the temporomandibular joint: *Oral Surgery, Oral Medicine, and Oral Pathology*, v. 58, p. 461-474.
- Romer, A.S., 1924, A radial exostosis in the fossil canid *Daphoenus*: *American Journal of Science*, v. 8, p. 235-240.
- Romer, A.S., 1964, Bone in early vertebrates, in Frost, H.M., ed., *Bone Biodynamics*: Little Brown, Boston, p. 13-37.
- Rothschild, B.M., 1982, *Rheumatology: A Primary Care Approach*: Yorke Medical Press, New York, 416 p.
- Rothschild, B.M., 1985, Diffuse idiopathic skeletal hyperostosis: misconceptions and reality: *Clinical Rheumatology*, v. 4, p. 207-212.
- Rothschild, B.M., 1987a, Paleopathology of the spine in Cretaceous reptiles, in Appelboom, T., ed., *Art, History and Antiquity of Rheumatic Disease*: Elsevier, Brussels, p. 97-99.
- Rothschild, B.M., 1987b, Diffuse idiopathic skeletal hyperostosis as reflected in the paleontological record: dinosaurs and early mammals: *Seminars in Arthritis and Rheumatism*, v. 17, p. 119-125.
- Rothschild, B.M., 1988, Stress fracture in a ceratopsian phalanx: *Journal of Paleontology*, v. 62, p. 302-303.
- Rothschild, B.M., 1989a, Skeletal paleopathology of rheumatic diseases: the sub-primate connection, in McCarty, D.J., ed., *Arthritis and Allied Conditions, 12th edition*, Lea and Febiger, Philadelphia, 1991, p. 3-7.
- Rothschild, B.M., 1989b, Paleopathology and its contributions to vertebrate paleontology: technical perspectives: *Journal of Vertebrate Paleontology*, v. 9, p. 36A-37A.
- Rothschild, B.M., 1990, Radiologic assessment of osteoarthritis in dinosaurs: *Carnegie Museum, Annals*, v. 59, p. 295-301.
- Rothschild, B.M., 1991, The testable hypothesis and inherent assumptions, in Rothschild, B.M. and Shelton, S., eds., *Paleopathology*: University of Texas Museum of Natural History, Austin, in press.
- Rothschild, B.M., 1992, The testable hypothesis and inherent assumptions: University of Texas Museum of Natural History, Austin, in press.
- Rothschild, B.M. and Berman, D., 1991, Fusion of caudal vertebrae in late Jurassic sauropods: *Journal of Vertebrate Paleontology*, v. 11, p. 29-36.
- Rothschild, B.M. and Martin, L., 1987, Avascular necrosis: occurrence in diving Cretaceous mosasaurs: *Science*, v. 236, p. 75-77.
- Rothschild, B.M. and Martin, L., 1992a, Paleopathology: Disease in the Fossil Record: CRC Press, Boca Raton.
- Rothschild, B.M. and Martin, L., 1992b, Frequency of pathology in a large natural trap cave with special remarks on erosive disease in the Pleistocene: University of Texas Museum of Natural History, Austin, in press.
- Rothschild, B.M. and Molnar, R.E., 1988, Osteoarthritis in fossil marsupial populations of Australia: *Carnegie Museum, Annals*, v. 57, p. 155-158.
- Rothschild, B.M. and Turnbull, W., 1987, Treponemal infection in a Pleistocene bear: *Nature*, v. 329, p. 61-62.

- Rothschild, B.M. and Woods, R.J., 1989. Spondyloarthropathy in gorillas: Seminars in Arthritis and Rheumatism, v. 18, p. 267-276.
- Rowley, M.J. and Rich, P.V., 1986. Immunoreactive collagen in avian and mammalian fossils: Naturwissenschaften, v. 73, p. 620-622.
- Russell, L.S., 1935. Musculature and functions in the ceratopsia: National Museum of Canada, Bulletin, v. 77, p. 39-48.
- Sawyer, G.T. and Erickson, B.R., 1985. Injury and diseases in fossil animals — the intriguing world of paleopathology: Encounters, May/June, p. 25-28.
- Schultz, H.-P., 1989. Three-dimensional muscle preservation in Jurassic fishes of Chile: Geologica de Chile, v. 16, p. 183-215.
- Sebes, J.I., Longston, J.W., Gavant, M.L. and Rothschild, B.M., 1991. Magnetic resonance imaging of growth recovery lines in fossil vertebrae: The American Journal of Roentgenology, v. 157, p. 415-416.
- Sigerist, H.E., 1951. A History of Medicine: Oxford University Press, New York, 564 p.
- Strauss, M.B., 1970. Physiological aspects of mammalian breath-hold diving: a review: Aerospace Medicine, v. 41, p. 1362-1381.
- Strauss, M.B. and Sampson, R.L., 1986. Decompression syndrome: an update: Physician and Sports Medicine, v. 14(3), p. 1-9.
- Tanke, D.H., 1991a. Paleopathologies in Late Cretaceous hadrosaurs (Reptilia: Ornithischia): behavioral implications, in Rothschild, B.M. and Shelton, S., eds., Paleopathology: University of Texas Museum of Natural History, Austin, in press.
- Tanke, D.H., 1991b. The rarity of paleopathologies in "short-frilled" ceratopsians (Reptilia: Ornithischia: Centrosaurinae): evidence for non-aggressive intraspecific behavior, in Rothschild, B.M. and Shelton, S., eds., Paleopathology: University of Texas Museum of Natural History, Austin, in press.
- Thomas, R.H., Schaffner, W., Wilson, A.C. and Paabo, S., 1989. DNA phylogeny of the extinct marsupial wolf: Nature, v. 340, p. 465-467.
- Thulborn, R.A. and Wade, M., 1984. Dinosaur trackways in the Winton Formation (mid-Cretaceous) of Queensland: Queensland Museum, Memoirs, v. 21, p. 413-517.
- Tyson, H., 1977. Functional craniology of the ceratopsia (Reptilia: Ornithischia) with special reference to *Eoceratops*: M.Sc. Thesis, University of Alberta, Department of Zoology, 339 p.
- Vance, T., 1989. Probable use of the vestigial forelimbs of the tyrannosaurid dinosaurs: Chicago Herpetology Society, Bulletin, v. 24, p. 41-47.
- Wang, X. and Rothschild, B.M., 1990. Bilateral osteochondroma on distal radius in *Hesperocyon* (Canidae: Carnivora): Journal of Vertebrate Paleontology, v. 10, p. 47A.
- White, F.N., 1970. Central vascular shunts and their control in reptiles: Federation Proceedings, v. 29, p. 1149-1153.
- Woolson, S.T., Dev, P., Fellingham, L.L. and Vassiliadis, A., 1986. Three-dimensional imaging of bone from computerized tomography: Clinical Orthopedics and Related Research, v. 202, p. 239-248.
- Wyckoff, R.W., 1980, in Hare, P.E., ed., Biogeochemistry of Amino Acids: Wiley, New York, p. 17.



The Mines and Minerals Division is on the move!

Our commitment to excellence continues in the Willet Green Miller Centre.

The following branches are relocating:

- Ontario Geological Survey Geoscience
- Ontario Geological Survey Information Services
- Mineral Development and Mine Rehabilitation
- Mining Lands

We look forward to providing our clients with a full array of services from our new location.

Moving Up!



The Final Phase



Ontario

Ministry of
Northern Development
and Mines